

## Haemangioma of the Frontal Sinus: A Case Report

TAREK S. JAMAL, FRCSI

*Department of Otorhinolaryngology, Faculty of Medicine & Allied Sciences,  
King Abdulaziz University, Jeddah, Saudi Arabia*

**ABSTRACT.** Haemangioma of the frontal sinus was not reported in the English literature until now. This paper is reporting the first case of lobular haemangioma of the right frontal sinus that was treated by surgical excision. Nine months after surgery, there is no evidence of recurrence clinically. The literature on this topic was reviewed.

**Keywords:** Haemangioma, Capillary, Frontal sinus

### Introduction

Although haemangiomas are common lesions of the head and neck, those of the nasal cavity and paranasal sinuses are rare<sup>[1, 2]</sup>. A review in English literature until 1997 revealed only 33 cases of maxillary sinus haemangioma. This study reports the first case of lobular capillary haemangioma of the right frontal sinus in a 9-year old Saudi boy.

### Case Report

The patient was a 9-year old healthy Saudi boy. This patient was presented to my clinic in August, 1999 with a two-months' history of swelling in the superomedial wall of the right orbit. There was no report of eye or ENT complaint associated with this swelling. His past medical history was unremarkable.

On examination, both ears, nose, and throat were normal.

There was a hard swelling about 1 x 1.5 cm in the superomedial wall of the right orbit. It was not tender. The skin over it was free and healthy. General examinations

---

Correspondence & reprint requests to: Dr. Tarek S. Jamal, Department of Otorhinolaryngology,  
King Abdulaziz University Hospital, P.O. Box 80215, Jeddah 21589,  
Saudi Arabia.

Accepted for publication: 06 May 2001. Received: 05 February 2001

and a routine investigation were normal.

A computerized tomography (C.T.) scan without contact (Fig. 1) showed features of slowly growing benign looking expansile lesion mostly in the location of the right frontal sinus with downward remodeling of the bony roof in the right orbit.

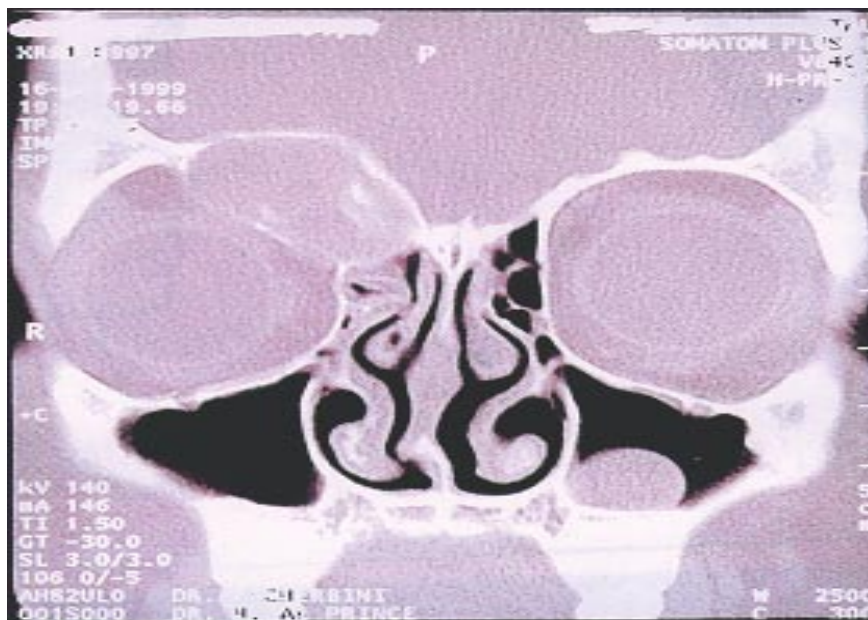


Fig. 1: A C.T. scan without contact showing the features of slowly growing benign looking expansile lesion in the location of the right frontal sinus with remodeling of the bony roof of the right orbit.

These features are highly suggestive of frontocele of the right frontal sinus and less likely of epidermoid regarding its location, patient's age, and sex. The orbit itself is essentially free apart from remodeled roof.

A complete removal of the lesion was performed through an external approach. The incision was about 1.5 cm long just beneath the medial end of the eye brow similar to the operation of trephining the frontal sinus (Fig. 2). A cut was made through the skin, subcutaneous tissue, and periosteum. The periosteum was then elevated from the bone of the floor in the frontal sinus. The remodeled bone of the floor in the frontal sinus was thin and easily removed by a small gauge and hummer. After opening the mucosa of the frontal sinus, bleeding started, and it was controlled by gauze packing soaked in a nasal decongestant gel. An inspection of the frontal sinus by 0° 4 mm sinuscope was performed. The lesion covered the floor of the sinus and its lateral wall. The removal of this variable-bleeding lesion was by curette and suction until clean by using the sinuscope. During surgery, the lesion bled freely after complete removal by curettage and gauze packing soaked in nasal decongestant gel was used several times until the bleeding stopped. The wound was closed with a drain. The drain continued to ooze serosanguineous secretions for five days. On the sixth postoperative day, the drain was removed. Two stitches were removed with the drain and the last stitch was removed one day later.

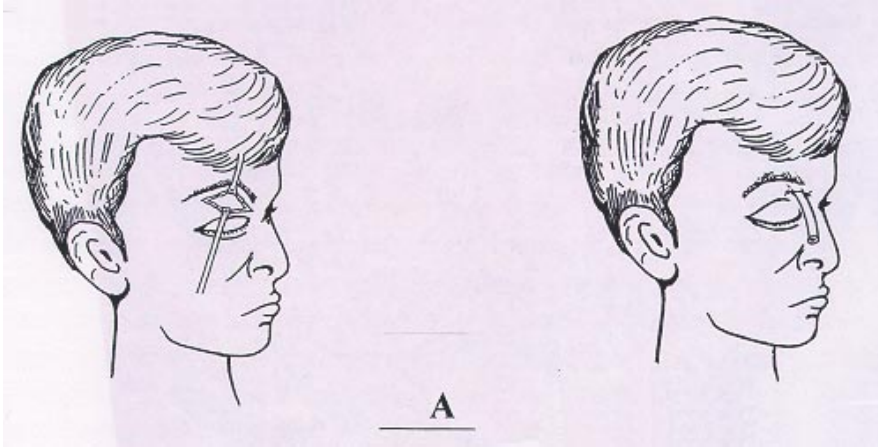


Fig. 2A: The site of the incision as a diagram.

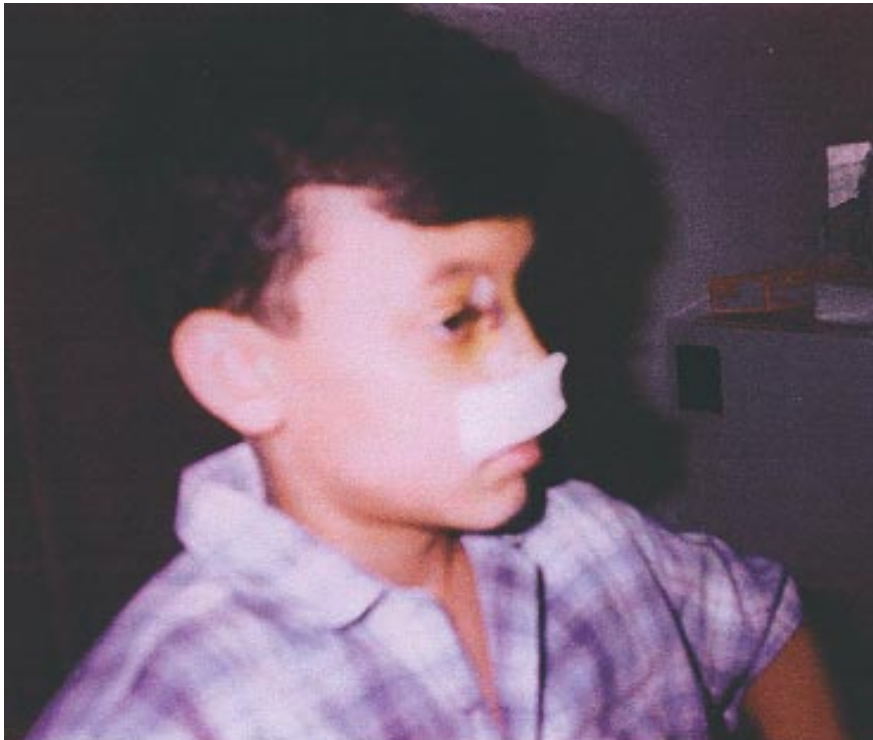

Fig. 2B: Photograph of the patient on the first postoperative day.

The microscopic appearance of the lesion (Figures 3A and 3B) showed a piece of

very vascular tissue with lobulated pattern and large areas of haemorrhage in the center. These features are consistent with benign vascular tumor (Lobular Capillary Haemangioma). Scatter calcified or dense hyaline acellular structure simulating psammoma bodies are seen in the fibrous septae between the lobules. No mitosis was seen. No cell anaplasia was present.

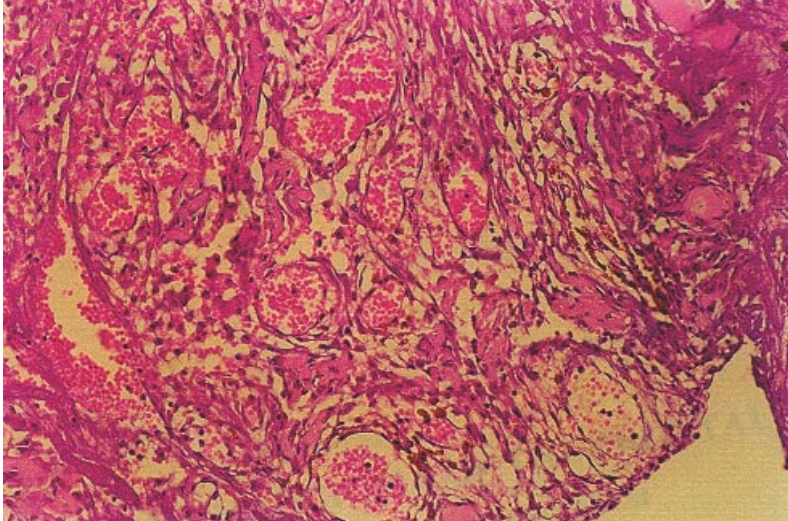


Fig. 3A. High power view showing proliferating spindle cells and formation of variable size capillary channels filled with blood.

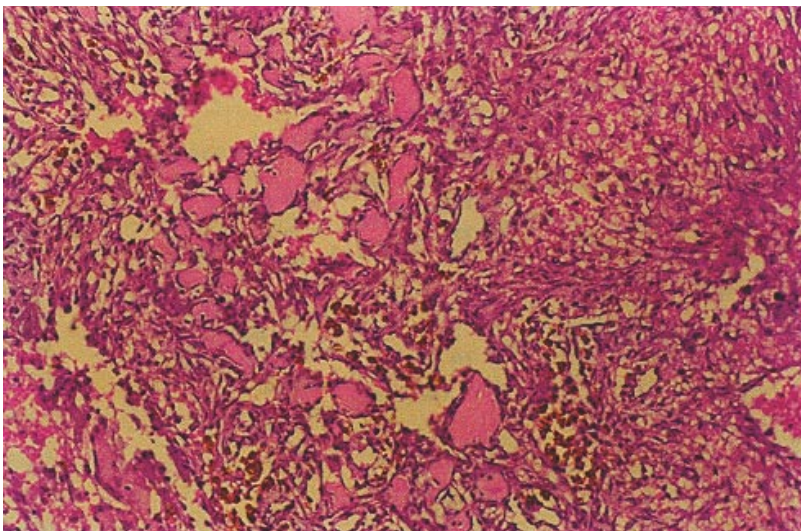


Fig. 3B. Intermediate power view showing spindle cell proliferation with small channels filled with blood. Scattered hemosiderin is seen.

Nine months after surgery, the patient remained healthy and free of the disease. A C.T. scan was requested, unfortunately, the patient did not have it done and disappeared.

### Discussion

Haemangiomas are common lesions especially in childhood. They have several clinical and histological varieties. Capillary haemangiomas usually arise from skin or mucous membranes. The lesions range from 1 - 2 mm to several centimeters. Haemangiomas are benign vascular lesion<sup>[3]</sup>. The majority of the haemangioma are present in the head and neck area. Although the histological findings of all of them are similar with only minor variations; their clinical features, management, and prognosis are different according to their location<sup>[4]</sup>. Therefore, the classic histological classification in capillary, cavernous, and mixed haemangiomas has no clinical relevance<sup>[5]</sup>.

It has been reported that over 20% of the benign non-epithelial tumours involving the nasal cavity, paranasal sinuses, and nasopharynx are capillary haemangiomas<sup>[6]</sup>.

The surgery was planned to excise a frontal mucocele, but after opening the right frontal sinus, a vascular mass was found, that was then easily removed down to the periosteum with suction and curettage. The bleeding was controlled by packing and the drain was left in place.

This is the first case of frontal sinus capillary haemangioma.

### References

- [1] **Batsakis JG, Rice DH.** The pathology of head and neck tumors: vasoformative tumors, part 9A. *Head Neck Surg* 1981; **3(3)**: 231-239.
- [2] **Batsakis JG, Rice DH.** The pathology of head and neck tumors: vasoformative tumors, part 9B. *Head Neck Surg* 1981; **3(4)**: 326-339.
- [3] **Batsakis JG.** *Tumors of Head and Neck, 2nd Edition.* Baltimore, MD: Williams and Wilkins & Co. 1984; 291-296.
- [4] **Raboso E, Rosell A, Plaza G, Martinez-Vidal A.** Haemangioma of the maxillary sinus. *J Laryngol Otol* 1997; **111(7)**: 638-640.
- [5] **Batsakis JG.** *Tumors of Head and Neck, 2nd Edition.* Baltimore, MD: Williams and Wilkins & Co. 1984; 291-296.
- [6] **Raboso E, Rosell A, Plaza G, Martinez-Vidal A.** Haemangioma of the maxillary sinus. *J Laryngol Otol* 1997; **111(7)**: 638-640.

# الورم الوعائي الدموي في الجيب الأنفي الجبهي تقرير عن أول حالة

طارق صالح جمال

قسم الانف والأذن والحنجرة ، كلية الطب ، جامعة الملك عبد العزيز  
جدة - المملكة العربية السعودية

المستخلص. هذه الحالة ورم وعائي دموي في الجيب الأنفي الجبهي الأيمن في طفل سعودي عمره تسع سنوات وهي أول حالة في المراجع الإنجليزية حتى الآن . عولجت الحالة باستئصال جراحي وبعد تسعة أشهر من الجراحة لم يكن هناك عودة للورم . وقد روجع ما نشر عن هذه الأورام في الجيوب الانفية .