

## Adenoids in Adults

TAREK S. JAMAL, FRCS (I)\*

*Department of Otorhinolaryngology, Faculty of Medicine & Allied Sciences,  
King Abdulaziz University  
Jeddah, Saudi Arabia.*

**ABSTRACT.** This is a prospective study of one hundred patients (18-38 yrs) with nasal obstruction as their main complaint. They were investigated clinically to verify the presence of adenoid enlargement, including nasal endoscopy and plain X-ray to the nasopharynx (soft tissue neck lateral view). Enlarged adenoid was diagnosed in seven (7%) patients. They were visualized endoscopically, shown radiologically and confirmed by histopathology. Adenoidectomy successfully relieved the patient's symptoms without recurrence for the follow-up period of an average of 18 months. Nasal endoscopic examination should be included in the diagnostic work-up of nasal disorders. If not available, X-ray to nasopharynx should be included in the investigation of adult patients with nasal obstruction. The diagnosis of adenoid enlargement in adults should not be disregarded on account of age only.

**Keywords:** Adenoids, Adults, Nasal endoscopy.

### Introduction

Although adenoids enlargement is frequently seen in children, its incidence and frequency in adults have not been widely reported. The nasopharyngeal tonsil is sub-epithelial aggregation of lymphoid tissues and called adenoids. Adenoid enlargement occurs most commonly between the age of three and seven years. Atrophy usually begins after 10 years of age and is complete before the age of 20<sup>[1,2,3,4]</sup>.

Although adenoid is the most common cause of nasal obstruction in young children, its occurrence in adults is uncommon. This could be the reason why that its diagnosis is easily missed.

---

\* Correspondence & reprint requests to: Dr. T.S. Jamal, P.O. Box 6615, Jeddah 21452, Saudi Arabia.  
Accepted for publication 21 October, 1995.

However, few authors have reported adenoid enlargement in adulthood<sup>[5,6]</sup>. The aim of the present study was to evaluate and examine the frequency of adenoid enlargement in a group of young adults present with nasal obstruction.

### Material and Methods

The present study included 100 young adult patients presented to otorinolaryngology (ORL) clinics at King Abdulaziz University Hospital, Jeddah, with nasal obstruction as their main complaint. Full history taking, ORL examination, nasal endoscopy and plain X-ray, were performed. Nasal endoscopic examination was carried out 10 minutes after spraying the nose with xylometazoline hydrochloride (1%) and xylocaine spray (4%) using 0<sup>0</sup>, 4mm endoscope. Plain X-ray film was requested for all patients (soft tissue neck lateral view). Patients diagnosed with adenoid enlargement underwent adenoidectomy. They were followed-up for a period ranging from 9 months to 2 years (mean 18 months). They have a history of trials of medical treatment. As the nasal appearance was misleading giving a picture of hypertrophic inferior turbinates, deviated nasal septum, non allergic or allergic rhinitis. Three of them were subjected to unsuccessful surgeries in the form of septoplasty, partial inferior turbinectomies with or without intra-nasal antrostomy.

### Results

The patient's age ranged from 18 to 38 years with a mean value of 26 years. Sixty three were males and 37 were females. The causes of the nasal obstruction are illustrated in Table 1. It shows 7 patients with adenoid enlargement. Table 2 shows the associated symptoms in which postnasal discharge was the most common complaint. The symptoms duration spanned between 9 months and 4 years (mean 1.5 years).

TABLE 1. Causes of nasal obstruction for the patients studied.

Aetiology of nasal obstruction	Number of patients
- Deviated nasal septum ± Allergic Rhinitis	43
- Allergic Rhinitis	30
- Vasomotor Rhinitis	7
- Adenoid enlargement	7
- Sinusitis	6
- Nasal polypi	4
- Hypertrophied inferior turbinate	3
<b>TOTAL</b>	<b>100</b>

Anterior rhinoscopic examination in 7 of the patients with adenoid enlargement revealed different findings as illustrated in Table 3.

Adenoid enlargement was diagnosed endoscopically as a swelling encroaching on the posterior septum almost occluding the choanae. In all the 7 patients, the X-ray films revealed soft tissue mass almost obliterating the air column of the nasopharynx (Fig. 1).

TABLE 2. The associated symptoms in the 7 patients with adenoid enlargement and nasal obstruction.

Associated Symptoms	Number of Patients
- Rhinorrhea	3
- Headache	4
- Snoring	4
- Nasal tone	3
- Deafness and/or Tinnitus	2
- Post nasal discharge	6

TABLE 3. Anterior rhinoscopic examination findings in the 7 patients with adenoid enlargement.

Anterior Rhinoscopic Findings	Number of patients
- Hypertrophied inferior turbinates (pale)	2
- Hypertrophied inferior turbinates (congested)	1
- Mucoïd nasal discharge	2
- Mucopurulent nasal discharge	1
- Mild deviated nasal septum	1

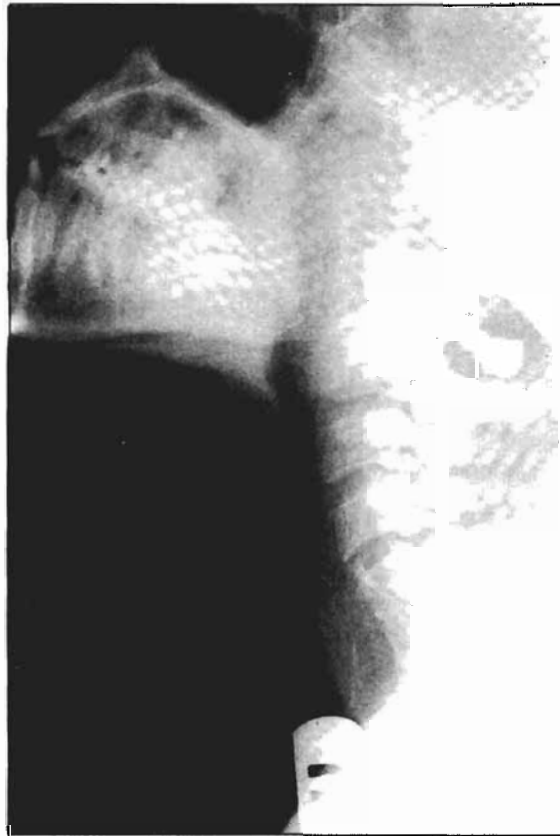

FIG. 1. An X-ray of soft tissue neck (lateral view) showing hypertrophy of adenoid causing narrowing of the air column.

Adenoidectomy was performed on all the patients with adenoid enlargement without interference neither with inferior turbinates nor the septum. The diagnosis was confirmed by histopathological examination (Fig. 2). All patients showed percentage of improvement in nasal breathing with disappearance of snoring and nasal tone. Rhinorrhoea improved in 2 cases (out of 3), headache in 2 (out of 4), deafness and tinnitus in 1 (out of 2) and postnasal discharge improved in 2 cases only (out of 6).




FIG. 2 A section shows adenoid tissue with lymphoid hyperplasia.

The patients were followed up for 9 months to 2 years (mean 18 months) without recurrence of the symptoms.

### Discussion

In the present study, adenoid enlargement was diagnosed clinically and radiologically and confirmed histopathologically in 7 young adult patients (7%), with nasal obstruction as their main complaint. The 7 patients underwent adenoidectomy without any nasal surgery. All patients were relieved of their nasal obstruction, snoring and nasal tone of speech. Except for postnasal discharge; other nasal symptoms, namely, rhinorrhea, headache and deafness were improved in 50-67% of patients studied. The patients were followed up for an average period of 18 months without recurrence of symptom. This has confirmed that adenoid enlargement was the direct cause of the patient's problem.

Patients complaint had started more than nine months previously (mean 1.5 years). Although they sought medical advice on more than on occasion, the diagnosis was overlooked. Adenoid enlargement is often considered in the differential diagnosis of nasal obstruction in adults<sup>[7]</sup>. The unfamiliarity of their presence and the lack of proper tools to visualize the nasopharynx are one of the causes of the failure in the diagnosis. It is obvious that posterior rhinoscopic examination could easily reveal the cause. Nev-

ertheless, it is not possible to visualize the nasopharynx in every patient with the post nasal mirror. Plain X-ray (lateral view) to the nasopharynx is a simple method for accurately determining the size of the enlarged adenoids<sup>[8,9]</sup>. Unfortunately, it is not routinely requested for cases of nasal obstruction in adults.

In the present study, anterior rhinoscopic examination of the 7 cases with adenoid enlargement revealed inferior turbinates in 3 cases which could possibly be due to distal lymphatic and venous obstruction<sup>[10]</sup>. A sign which was not unlike vasomotor or allergic hypertrophies turbinates. Nasal secretion was present in 3 patients which could be attributed to sinusitis, the treatment of which was ineffective due to nasopharyngeal obstruction. So unless the possibility of adenoids in adults is borne in mind, even with the presence of positive findings on nasal examination which can explain the patient's symptoms, its diagnosis can be easily missed.

Nasal endoscopic examination is a major break through in the diagnosis of nasosinus diseases. It could accurately diagnose the nasopharyngeal adenoid, its size, shape and degree of encroachment on the airway. It should be included routinely in clinical examination in any nasal sinus related complaints. Equally valuable in the cases studied was the use of plain X-ray lateral view to the nasopharynx. It could delineate the adenoid soft tissue shadow and the compromised nasopharyngeal air column. However, it should be born in mind that a nasopharyngeal mass in adults should alert the suspicion of malignancy.

In conclusion, the possibility of adenoid enlargement as a cause of nasal obstruction in adults should be considered in every patient. Nasal endoscopic examination is an invaluable tool in the clinical assessment of patients with nasal disease. If not available, X-ray lateral view of the nasopharynx should be added in the investigation of patients with nasal obstruction. Also their routine application may show other hidden causes of nasal obstruction, e.g. an enlarged posterior end of the inferior turbinates.

#### References

- [1] **Holender AR.** The lymphoid tissue of the nasopharynx. *Laryngoscope* 1959; **69**: 529-535.
- [2] **Gray LP.** The T's and A's problem-assessment and reassessment. *J. Laryngol. Otol* 1977; **91**: 11-32.
- [3] **Hibbert J.** Tonsils and adenoids in Scott-Browns disease of the ear, nose and throat (**Kerr AG, Evans JNE.** Eds.) *Otorhinolaryngology* 5th Edn. Butterworth-London 1987; 368-386.
- [4] **Fujiyoshi T, Watanabe T, Ichimiya I, Mogi G.** Functional architecture of the nasopharyngeal tonsil. *Am. J. Otolaryngol* 1989; **10**: 124-131.
- [5] **Haffner DK.** Pathology of the tonsils and adenoids. *Otolaryngol. Clin.N. Am.* 1987; **20**: 279-286.
- [6] **Kamel RH, Ishak EA.** Enlarged adenoid and adenoidectomy: endoscopic approach and histopathological study. *J. Laryngol. Otol* 1990; **104**: 965-967.
- [7] **Kennedy DW, Zinreich SJ, Rosebaum AE, Johns ME.** Functional endoscopic sinus surgery theory and diagnostic evaluation. *Brit J. Otolaryngol* 1987; **111**: 576-582.
- [8] **Maves MD.** Tonsil and adenoids in Otolaryngology head and neck surgery (**Cummings CW, Schuller DE.** Eds) *General Surgery* 2nd Ed. C.V. Mosby Company; St. Louis, Toronto 1986; 1117-1127.
- [9] **Goldmann LJ, Brachmann AJ.** Soft tissue roentgenography of the nasopharynx for adenoids. *Brit J. Otolaryngol* 1958; **68**: 1288-1293.
- [10] **Hibbert J, Stell PM, Wright A.** The value of physical signs in the diagnosis of enlarged adenoids. *Clinic. Otolaryngol* 1980; **5**: 191-194.

## الزوائد الأنفية في الكبار

طارق صالح جمال

قسم الأذن والأنف والحنجرة

كلية الطب والعلوم الطبية ، جامعة الملك عبدالعزيز

جدة - المملكة العربية السعودية

المستخلص : هذه دراسة لمائة مريض تتراوح أعمارهم بين ١٨- ٣٨ سنة ويشكون أساسا من انسداد بالأنف . درست هذه الحالات اكلينيكيًا مع عمل منظار وأشعة للبلعوم الأنفي لمعرفة ما إذا كان سبب الانسداد هو الزائدة الأنفية (نسيج لفاوى متضخم يعوق التنفس) . لقد وجد أن سبب الانسداد في ٧٪ من الحالات هو الزائدة الأنفية . وقد تأكد ذلك بالمنظار وبالأشعة وبالفحص المجهرى لتلك الزوائد بعد ازالتها جراحيا . إزالة تلك الزوائد جراحيا أدى إلى تحسن تام فى شكوى أولئك المرضى بدون عودة الأعراض مع متابعة المريض حوالي ١٨ شهرا بعد الجراحة . الفحص المنظاري للبلعوم الأنفي يجب أن يعمل في كل حالات الشكوى الأنفية وإذا لم يتوفر نقوم بعمل أشعة للبلعوم الأنفي لكل المرضى البالغين اللذين يشكون من انسداد بالأنف وتشخيص الزائدة الأنفية في البالغين يجب أن لا تتغاضى عنه اعتمادا على عمر المريض حيث إنها أكثر شيوعا في الأطفال وتضمم عادة بعد سن العاشرة .